

Anal Fistulae – The Changing Concepts

PN Joshi*, Parvez Sheikh**

Abstract

Lots of confusion prevail about the aetiology, classification and management of Anal fistula. Anal fistula occurs as a result of suppuration of anal gland, which spreads into various fascial plains. The revised classification of anal fistula will provide the guidelines to surgeon to plan a particular surgical procedure. Excision of anal gland, conservative surgical approach and reconstruction of anus after Fistulectomy helps in preserving anal continence, early recovery and good aesthetic results.

Anal fistula is a track, which communicates with anal canal by means of an internal opening in continuity with one or more external openings. The external opening may be in perianal, ischiorectal or perineal areas. The blind fistula does not have any external opening. The fistulae to be discussed are those, which arise from the infection of anal gland (cryptogenic origin). Acute infection of anal gland leads to an abscess formation, while chronic stage of the infection presents as an anal fistula. The pus culture contains gut organisms.

Anal gland

Above each anal valve is a little pit or pocket known as anal crypt or sinus of Morgagni. In the crypt lies the opening of the duct of anal gland. There are about four to eight anal glands in the normal anal canal. Each has a direct opening into the apex of an anal crypt and occasionally two glands open into the same crypt. About half the crypts in anal canal have no glands opening in them. Traced outwards from its cryptal opening, the average gland has a short tubular portion in

the submucosa, which quickly branches into a racemose structure of widely ramifying ducts. Some glands appear to be confined entirely to the submucosa but two-thirds of them have one or more of their branches enter the internal sphincter, and half of them pierce it completely to reach upto longitudinal layer. The general direction of the glands is outward and downwards but never upwards above the level of anal valves. The epithelium lining is of stratified columnar type. It is doubtful whether the anal glands have any secretory function. Their surgical significance is that they provide an avenue of infection from the anal canal to submucous or Intersphincteric abscess.

Classification of anal fistulae

The primary internal opening is always near the dentate line. Any internal opening above this is always a secondary internal opening which is very rare. The primary internal opening may appear higher than the level of the anal crypt because of traction and distortion caused by fibrosis.

It is important to classify fistulae, which can only be done finally during surgical exploration. It is not always possible to classify a fistula because of the distortion of normal anatomy. However it provides an anatomical

*Colo-Rectal Surgeon, Mumbai - 400 026.

**Laparoscopic and Colo-Rectal Surgeon*, Mumbai- 400 002.

basis for correct surgical management. The authors have found that Goodsall's rule is not always accurate for anterior openings, as many fistulas with anterior openings were not anterior fistulas, but were actually anterior openings of posterior horseshoe fistulas.

Classification of fistulae

1. Intersphincteric
2. Trans-sphincteric
3. Suprasphincteric
4. Multiple, complicated unclassified
5. Extrasphincteric

What is high fistula?

Since all anal fistulae have their primary internal opening in the anal crypt and as the source of infection is in anal gland, all of them can be cured only if the anal gland is removed during surgery. Failure to do this will result in recurrence of the disease. Hence the word high fistula has lost its relevance. Lot of confusion exists over the definition of a high fistula. Parks and Stitz have defined "A high fistula is one where the track or extension of fistula reaches a level above the puborectalis, and whether or not this high track is in the summit of the Ischio-rectal fossa or has penetrated into the suprlevator space"

This broad definition provides guideline to the surgeon while planning its surgery.

1. Intersphincteric fistula

Suppuration of anal gland forms an abscess, which spreads between internal and external sphincters (Intersphincteric space)

- (i) *Low Intersphincteric Fistula (Figs. 1a, 1b):* If the Intersphincteric abscess tracks downward it presents as a perianal abscess. It may burst on its own or may be incised. If complete healing does not occur it forms a low anal Intersphincteric

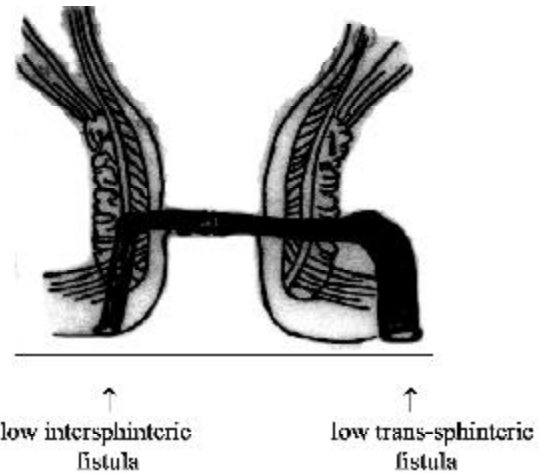


Fig. 1a :

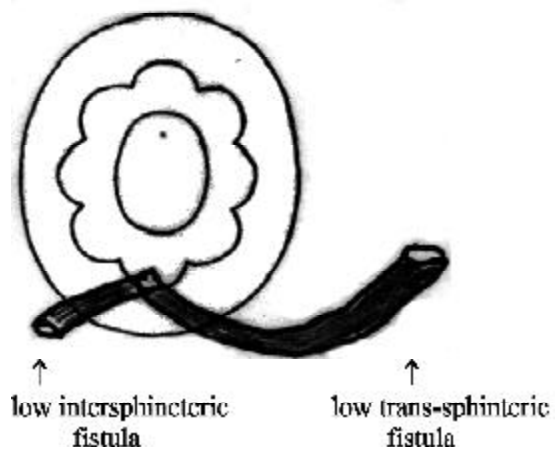


Fig. 1b :

fistula. Its internal opening is in the anal crypt just above the pectinate line. Its external opening is usually at the anal verge or sometimes little far away if the abscess has tracked subcutaneously.

- (ii) *High Intersphincteric Fistula (Figs. 2a & 2b) :* If the Intersphincteric abscess tracks upward, it forms an intersphincteric abscess previously known as submucous abscess. It may burst into the anal canal usually at the anal crypt or may be incised. If complete healing does not occur it forms high internal Intersphincteric

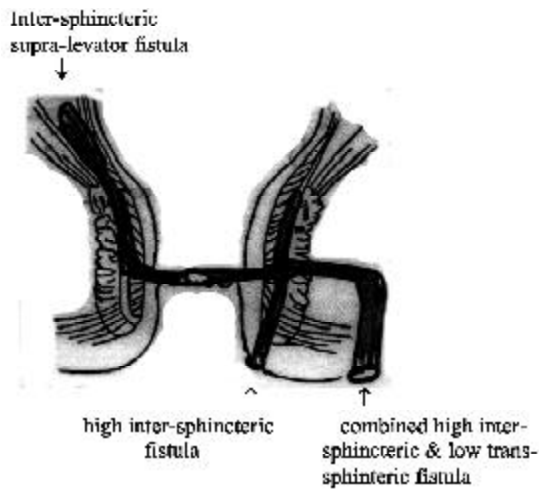


Fig. 2a :

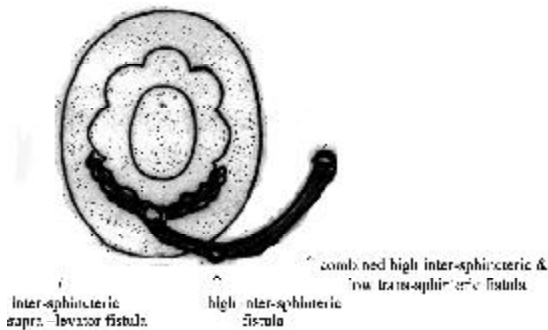


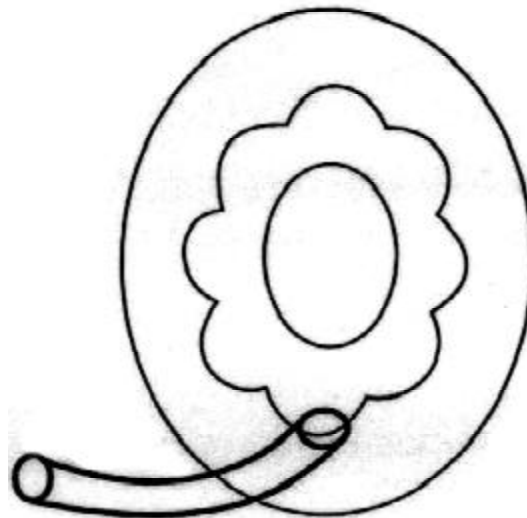
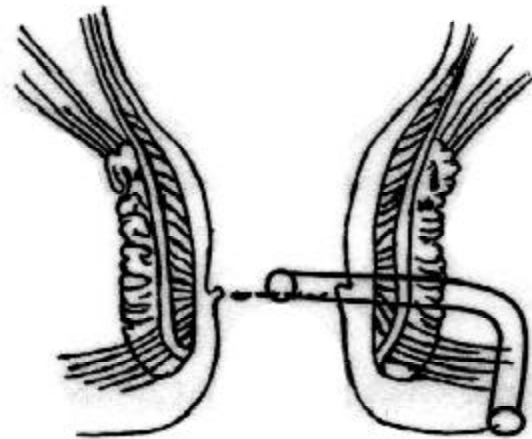
Fig. 2b :

fistula. The internal opening is in the anal crypt. If the intersphincteric abscess was incised higher up there may be a secondary internal opening higher up in addition to primary internal opening

- (iii) *Combined high and low Intersphincteric Fistula (Figs. 2a and 2b)* : In this case Intersphincteric abscess has spread upward and downwards resulting into intermuscular abscess inside and perianal abscess outside. The resultant fistula has an external opening at the anal verge and internal opening in the anal crypt with or without secondary opening higher up.

2. Trans-sphincteric fistula

If the suppuration of anal gland traverses



Figs. 3a,b : Low trans-sphincteric fistula.

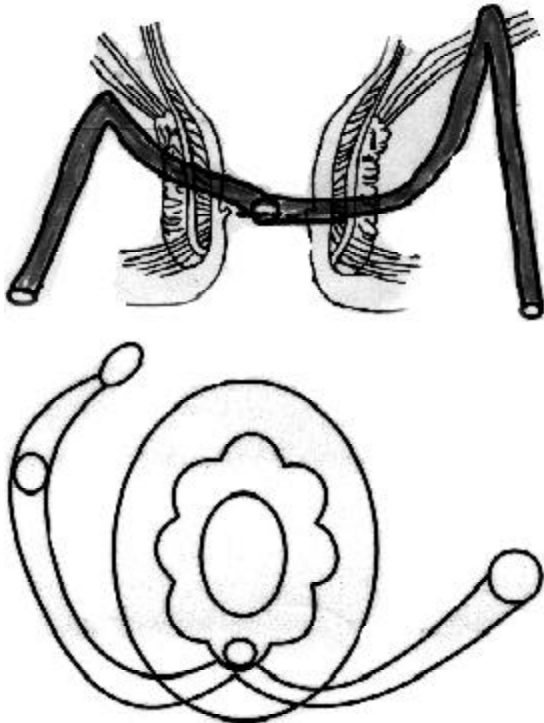
through the external sphincter it enters into the ischioanal fossa. This forms an ischioanal abscess. It is either incised and drained or may burst on its own. If complete healing does not occur it will persist as trans-sphincteric fistula.

- (i) *Low trans-sphincteric fistula (Figs. 3a and 3b)* : It has a track, which has an internal opening at the level of pectinate line and runs downwards in the ischioanal fossa. The external opening is somewhere near the outer side of the external sphincter or at the site of incision.

- (ii) *High trans-sphincteric fistula (Figs. 4a and 4b)* : This type of fistula has the internal opening just like low trans-sphincteric fistula. The fistulous track after traversing through the external sphincter runs upward upto the summit of ischiorectal fossa but is below the levator ani, from there it turns downwards through the ischiorectal fossa. Its external opening is usually away from anal verge or is at the site of incision.
- (iii) *Combined Intersphincteric and Trans-sphincteric fistula*: intersphincteric abscess or high intermuscular abscess when co-exists with ischiorectal abscess the resultant fistula is the combination of both(Figs. 2a and 2b).

3. Suprasphincteric or Supralelevator fistula

- (i) *Intersphincteric supralelevator fistula (Fig*



Figs. 4a,b : High trans-sphincteric and supra Levator fistula.

2a): When intermuscular abscess tracks upwards in the supralelevator space the resultant fistula is termed as intersphincteric supra-levator fistula. It usually has only internal opening in the anal crypt or may be associated with an external opening at the anal verge.

- (ii) *Trans-sphincteric supra-levator fistula (Figs 3a and 3b)* : Ischiorectal abscess tracks upwards through levator ani muscle to form a supralelevator abscess. Sometimes while draining ischiorectal abscess friable levator ani muscle may get perforated providing an avenue to supralelevator extension. The resultant fistula is trans-sphincteric supralelevator fistula
- (iii) *Combined Inter-sphincteric and trans-sphincteric fistula* : This type of fistula is as a result of supralelevator spread from intermuscular and ischiorectal abscess.

Vary rarely these fistulae may have a secondary opening into the rectum but more often they terminate into the blind end.

4. Complicated unclassified high anal fistula (Figs 5, 6a and 6b)

The source of infection is anal gland. The supralelevator abscess tracks higher up in retroperitoneal and or preperitoneal spaces. The condition mimics acute peritonitis. On exploration it is found that infection is restricted to extra peritoneal spaces and there is no peritonitis. Plain x-ray abdomen and CT scan will also indicate presence of gas in extra-peritoneal spaces due to gas forming organism. The patient is in severe septicaemia. After the drainage of pus, the fistula persists. Fistulogram will show the dye tracking down to ischiorectal fossa or into the anal canal through its internal opening. Rarely it may track through intersphincteric space. Author has nine cases of this type of

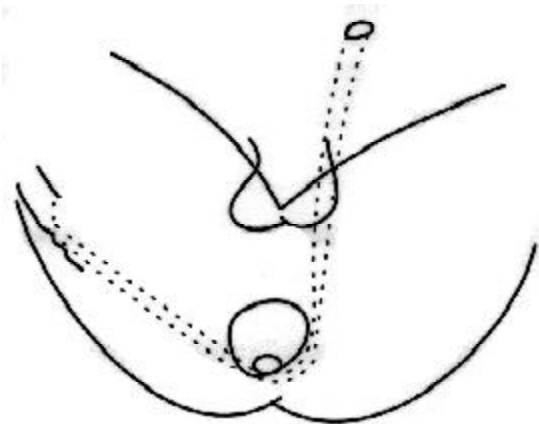


Fig. 5 : Unclassified high anal fistula.

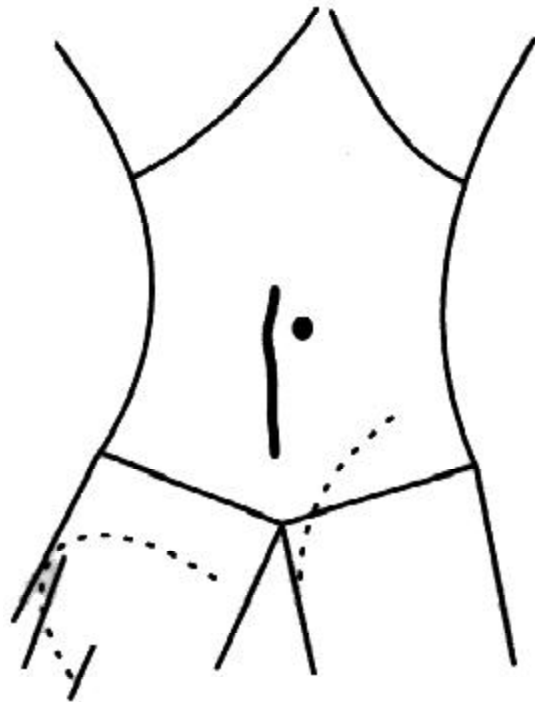


Fig. 6b : Complicate unclassified high anal fistula having preperitoneal, retroperitoneal spread.

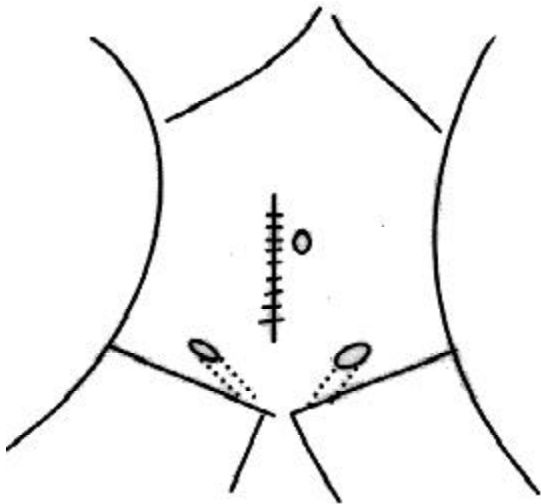


Fig. 6a : Complicated unclassified high anal fistula. Preperitoneal, retroperitoneal and Spreading into deeper fascial plains of thigh.

fistula.

5. Extra-sphincteric fistula (Fig 7)

These are not anal fistulae in its true sense since the origin is not from the infection of anal gland. Acute appendicitis, Diverticulitis, Salpingitis, Lymphadenitis may result into pelvic abscess which tracks downwards through levator into ischiorectal fossa or it may burst through rectum or vagina or both. Leak from anastomotic site after anterior

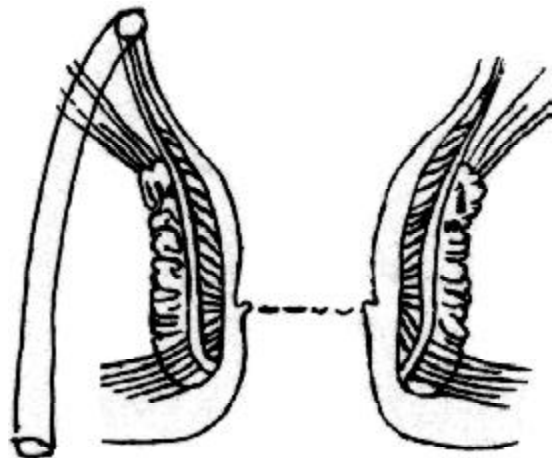


Fig. 7 : Extra-sphincteric fistula.

resection or penetrating injury or drain put through ischiorectal fossa can result into extra-sphincteric fistula. Fistulogram helps in locating its site of origin

Ischiorectal abscess may spread in the subcutaneous plane into the thigh and/or leg.

The resultant fistulous track is superficial with internal opening in the anal crypt in the posterior midline (one case) (Fig 5).

Perianal or Ischioirectal abscess may track towards scrotum or vulva and then to groin in the subcutaneous superficial plane. The resultant fistula has an internal opening into the anal crypt. (Five cases) (Figs. 8 and 9)

Vary rarely the ischioirectal abscess may penetrate the deeper fascial compartments of thigh. It may track behind the greater trochanter or may track in front through abductor compartment. The deep thigh abscess is not associated with osteomyelitis of femur. The dye injected through an

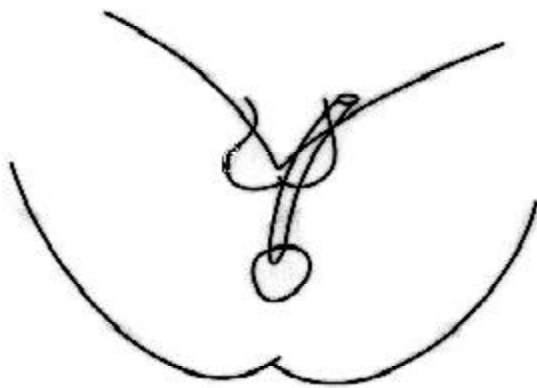


Fig. 8 : Anterior anal fistula spreading to scrotum and groin.

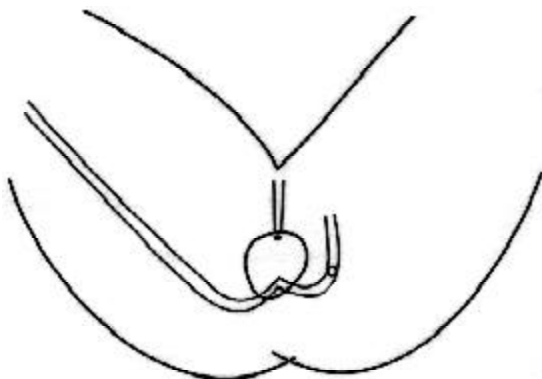


Fig. 9 : Posterior trans-sphincteric fistula spreading to thigh and gluteal region.

external opening in the thigh enters ischioirectal fossa and anal canal. Author has treated one case of this type of fistula, associated with pre-peritoneal fistula on the other side (Figs 5 and 6a).

Examination: Proper inspection may reveal one or more external openings. Sometimes it may be relatively inconspicuous and detected when pus is caused to escape by gentle palpation over some part of surrounding skin. In many longstanding cases opening may be lying underneath a nodule of exuberant granulation tissue. The opening may be closed under the scar of previous incision. When associated with pruritus the sore looking perianal skin may conceal the external opening due to oedema and congestion. If associated with chronic anal fissure the external opening is concealed by the sentinel pile. Finally the position of the opening or scar must be noted down diagrammatically.

Palpation: Palpation of perianal region may result in expression of pus and may give some indication of probable position of fistulous track. In simple direct low anal fistula the track can generally be felt as a distinct rod of induration extending in a straight line, from external opening to internal opening. If one inserts index finger in the anal canal one may feel an actual internal opening or an area of induration. With the help of thumb and index finger or if necessary with the help of other hand one can probably trace the entire course of the fistulous track. This should be marked out in the diagram. In a semi-horseshoe fistula this will be on one side while in complete horseshoe fistula the tracks are on both sides. If the track is very thin, one gets indication by exerting digital pressures if any tenderness can be elicited. In majority of the cases the internal opening can be located and is usually at the level of anal crypt and most

frequently in the posterior mid-line. If the track is direct the internal opening is in the line of the external opening. The same is true about anterior semi-horseshoe or horseshoe fistulae. It is important to locate the situation of the internal opening since it gives a good guideline of the course of the fistulous track. Even if the external opening is situated in the anterior compartment right upto the root of the scrotum or vulva and if the induration is felt into the posterior mid-line, it indicates that the fistula is a posterior semi-horseshoe running a curved course passing through ischio-rectal fossa and running towards posterior mid-line. Under these circumstances one may not be able to palpate the track in the ischio-rectal area, since it is deeply situated. After having ascertained all these — one should palpate the rectum above the puborectalis sling to find out if any intermuscular track is present. This is again felt as indurated tender bulge or ridge usually on lateral side. This will indicate that the patient also had intersphincteric abscess, which has not only tracked outside but has also tracked upwards in the intermuscular plane. Very rarely one may find another internal opening higher up which is felt as an opening or as an indurated nodule. All these must be diagrammatically recorded.

Probing the fistulous track: It is an unnecessary procedure, which is painful for the patient. It should be done at the time of operation after the patient is anaesthetized. No force should be exerted, as it is likely to create false passage.

Proctoscopy and Sigmoidoscopy: Proctoscopy may show the internal opening. This is often revealed by the escape of pus from it. It may alternatively demonstrate a hypertrophied papilla covering the internal opening or may be in the form of pouting granulation tissue. Sigmoidoscopy is

necessary to find out any coexisting disease like amoebic proctitis, worm infestations, inflammatory bowel disease or neoplasm.

Investigations : Fistulogram, Ultrasound study with an intra rectal probe, CT Scan, MRI studies and Chest X-ray are useful investigations. In a complicated fistula sinogram will show the extent of fistulous tracks. Ultrasound study provides information of muscular defects created following previous surgery. Chest X-ray should be done to detect existence of Pulmonary Tuberculosis, as this will provide the guideline in the management of fistula. However proper clinical examination provides maximum information.

Management

Prevention : Prevention of anal fistula is possible. In acute stage while abscess is being incised an attempt should be made to locate the site of anal gland. A careful examination of anal canal with a self-illuminated Sym's speculum will show puckered depression in the anal crypt or a bead of pus may escape on gentle pressure. The abscess can be aspirated with a wide bore needle and Methylene blue mixed with few drops of hydrogen peroxide when injected may appear in the anal crypt. Thus it is possible to excise or scoop out the anal crypt just like Fistulotomy wound. An acute abscess dealt like this will almost heal without any fistula formation.

The intermuscular abscess should be drained through the anal crypt instead of incising it higher up. Unhealthy mucosa around the crypt should be trimmed to provide adequate drainage.

Surgical Management of anal fistula

- (1) Fistulotomy
- (2) Fistulectomy
- (3) Fistulectomy with primary wound closer

- (4) Conservative surgery (author's procedure)
- (5) Fistulectomy with skin grafting
- (6) Fistulectomy with covering colostomy
- (7) Use of Seton
- (8) Ksharsutra
- (9) Chemical destruction or cauterization of fistula

Anaesthesia : Epidural anaesthesia is the most suitable and safe. For complicated anal fistula an epidural catheter can be left for two or three days to make post-operative dressings most comfortable. Spinal/epidural anaesthesia should be preferred to general anaesthesia as the amount of bleeding is much less, which makes surgery more comfortable. General anaesthesia with muscle relaxants necessitates endotracheal intubation. It is always possible to identify puborectalis sling under any anaesthesia. It can be hooked with an index finger inserted above the ano rectal ring in the rectum. It is a false statement that the relaxation of sphincters makes it difficult to identify the puborectalis sling.

Position : Lithotomy position is the most suitable position since visualization of the posterior quadrant of anal canal is excellent. This is so as majority of fistulae have their internal opening in the posterior mid line. It is ideally suited for all complicated fistulae when external opening is far away from anal verge or placed anteriorly near the root of scrotum. However most of the Americans prefer to operate in jack-knife position and under general anaesthesia. In our experience both surgeon and anaesthetist are not very happy to operate the patient in this position under general anaesthesia.

Straight rods are preferred since patient can be put into extended flexion with great ease and the buttocks can be brought down beyond the edge of the operation table.

If there is a central slot which most of the operation tables have a metal plate to cover it up prevents the buttocks sagging down. A small sandbag or an arm board can be passed under the buttocks for better visualization. The sticking plaster can be applied to buttocks to retract the cheeks of the buttocks. It is preferable to paint the buttocks with tincture benzoin prior to application of sticking plaster, since it provides firmer adhesive effect.

For draping leggings with 12" square hole is preferable to use of multiple towels and sheets, which are bit difficult to maintain in position. Raised table with head low position provides an excellent view.

Equipments: Proper lights and their adjustment is absolutely necessary. Fibre optic cable and self-illuminated Syme's speculum provides better illumination.

Modified Syme's speculum: One end of the speculum is straightened out and the speculum should be at the right angle or slightly obtuse to provide proper viewing of anal canal. Self-illuminated has an added advantage.

Right angle retractors, Allis forceps, Babcock's forceps, cautery, and sponge-holding forceps for mopping the wound since it avoids interference of assistant's hand.

Suture material: 2-0,3-0 chromic catgut 3-0 Vicryl rapid.

Infiltration solution: adrenaline in saline (1 into 150,000 dilution).

Malleable fistula probe director, crypt hooks.

2 ml of Methylene blue with five drops of hydrogen peroxide.

Small canula or scalp vein (cut the needle) to be attached to the syringe.

After draping the patient in lithotomy position a thorough examination should be carried out. Track should be palpated from

the external opening upto the internal opening. Intersphincteric track can be palpated in the anal canal, which feels like a ridge. Any extension to the opposite side can be detected by palpating the entire anal canal. Internal opening can be located as already mentioned in clinical examination.

Rest of the anal canal should be inspected for any coexisting pathology like haemorrhoids, fissure, polyp, hypertrophied papillae etc. Any sphincteric defect can be assessed by gentle palpation. The retracted stumps of sphincters can also be located. Methylene blue when injected through external opening will emerge through internal opening unless it is blocked or distorted by fibrous tissue.

Infiltration : The area surrounding fistulous track is infiltrated with saline adrenaline solution. This prevents unnecessary oozing and dissection of track becomes much easy. Liberal use of cautery helps in prevention of profuse bleeding, as the perineum is very vascular due to rich blood supply. Bleeding is much more if general anaesthesia is given since there is peripheral vasodilatation.

(1) *Fistulotomy* (Fig 10) : This procedure is preferred when fistulous track is short and external opening is near the anal verge. Low intersphincteric and trans-sphincteric fistulae usually have a short track. The fistulae of recent origin i.e. which have developed following incision and drainage of abscess have their tracks lined by granulation tissue and minimal or no fibrous tissue. The fistula director probe is passed from external opening, which will emerge through the internal opening. The entire track is laid open. The unhealthy granulation tissue is scooped out. The unhealthy mucosa surrounding the internal opening is

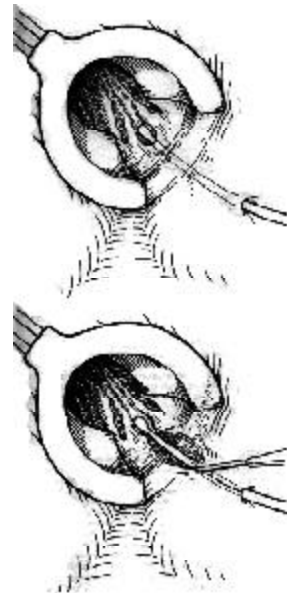


Fig. 10 : *Fistulotomy*

trimmed. The indurated granulation tissue with anal gland is excised, any hypertrophied papillae nearby is excised since it is indicative of anal gland infection. Digital palpation helps in detecting the underlying infected gland, which feels like a nodule. The skin margin is trimmed so as to create a saucer shaped wound. One should make sure that entire pathology is removed. Application of gauze soaked with hydrogen peroxide helps in identifying unhealthy tissue, which appears brown, while the healthy tissue appears pink. To prevent oozing from submucosa the mucosal flap of the anal canal is sutured to the underlying muscle tissue by taking running sutures using 3-0 chromic catgut. Even the skin edges can be anchored to reduce the raw area.

(2) *Fistulectomy* (Fig. 11) : The indications of Fistulectomy are same as fistulotomy. In a chronic fistula the track is surrounded by dense fibrous tissue unless the entire track is excised the healing of

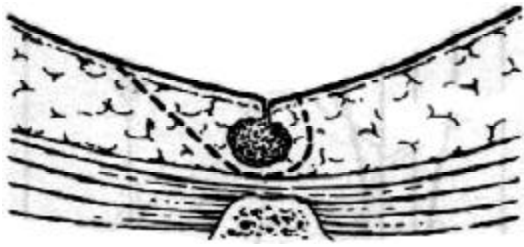

Fig. 11 : *Fistulectomy.*

the wound gets delayed. If the track is epithelialised it needs to be excised. The track is laid open like fistulotomy and then the fibrous track is completely excised. As an alternative a circular incision is made around the external opening. The fistulous track is held with Allis forceps and followed upto internal opening by making sharp cults around the fistulous track. The track is not opened and excised in Toto upto internal opening. Mucosal flap is sutured as done after fistulotomy and similarly additional skin sutures reduce raw area.

(3) *Fistulectomy with primary wound closure* (Figs. 12 and 13) : Primary wound closer is feasible if care is taken to preserve as much of skin and mucosa. The edges of mucosa and skin are approximated by 2-0 Chromic Catgut or 3-0 Vicryl rapid by taking deep bites. The wound should be sutured without tension and edges should lie in proper apposition. There should not be any dead space underneath the suture. If there is lot of dead space a tube drain or suction drain should be applied to prevent any collection underneath. If there is no dead space, wound heals well with good results. If there is any evidence of collection underneath with purulent discharges, sutures must be cut to convert it into Fistulectomy wound.

(4) *Fistulectomy with partial wound closure:* If there are multiple external openings

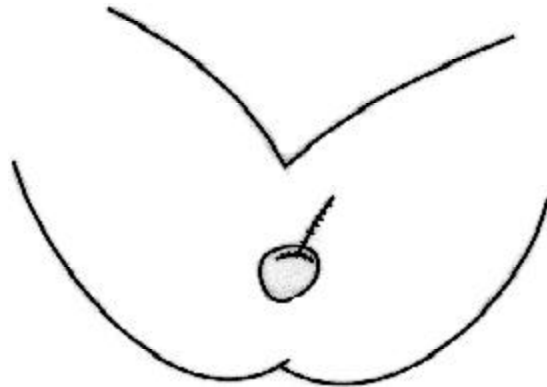


Fig. 12 : *Fistulectomy with primary wound closer.*

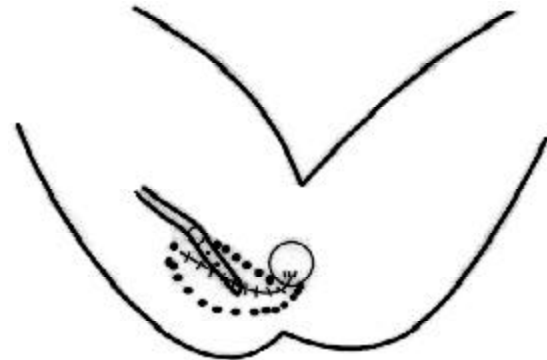


Fig. 13 : *Fistulectomy with primary wound closer and Suction drain*

fistulectomy will leave behind a large external wound. After anchoring the mucosa to the underlying muscle tissue, the skin flaps are mobilized to reduce the raw area. This enhances early healing of fistulous wound.

(5) *Fistulectomy with skin grafting* (Fig.14) : After fistulectomy some prefer to do immediate skin grafting. Majority of the surgeons prefer to do secondary skin grafting when wound is healing with healthy granulation tissue. Split skin graft taken from thigh is fixed with interrupted sutures and held in apposition by pressure dressing for 48 hrs or till next bowel movement. In 75% of cases it takes well.

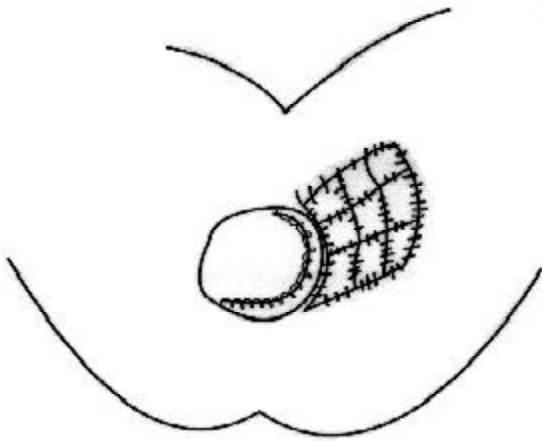


Fig. 14 :Fistulectomy with split skin grafting.

Parks conservative fistulotomy : Parks (1961) emphasized the importance of removing the intersphincteric abscess, anal gland and the fistulous track. In this procedure he has advocated the excision of anal gland along with corresponding part of the internal sphincter, trimming out the surrounding mucosa, and excision of intersphincteric abscess. The rest of the fistulous track was either curetted or cored out laterally with preservation of external sphincter.

Modified conservative fistulectomy with reconstruction of anal defect (author's procedure) (Figs. 15a and 15b) - This procedure is advocated for all types of trans-sphincteric fistulae, combined trans-sphincteric and intersphincteric fistulae and supralevator fistulae.

Patient is operated in lithotomy position if necessary with extended hyper flexion and buttocks projecting beyond the edge of the table. Fistulous track is probed to assess its direction and extension. If track is distorted by extensive fibrosis and or if the internal opening is blocked it would be difficult to probe. In that case probe is withdrawn since if force is applied it will create false passage. After this 2 to 3 ml of Methylene blue mixed with few drops of hydrogen peroxide is

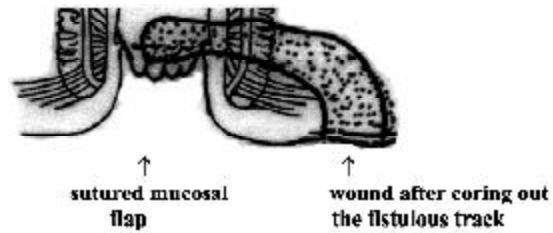


Fig. 15a :

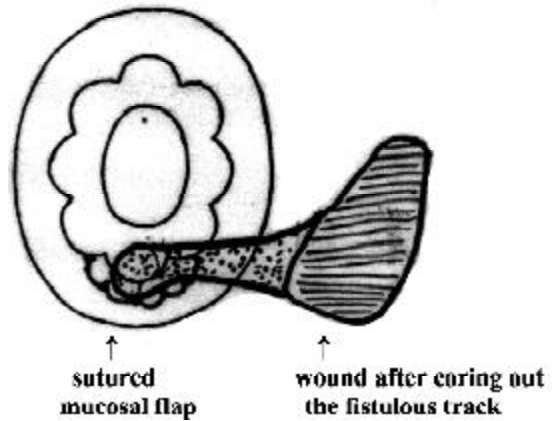


Fig. 15b :

injected through the external opening. If the internal opening is patent, dye will emerge through it into the anal canal and no more dye needs to be injected. If the internal opening is blocked no dye will appear in the anal canal, instead it will regurgitate back. After this the area surrounding the fistulous track and submucosa around the internal opening are infiltrated with solution containing adrenaline in saline (1 in 150,000)

Low trans-sphincteric fistula

An elliptical cut is made around the external opening with no 11 or no 15 blades. The track is dissected towards its internal course. All the bleeders are cauterized. The fistulous track is cored out taking care to prevent opening it. If necessary the wound can be enlarged inward. The track is dissected under direct vision with the help of small retractors and illumination from fibre optic cable. When the dissection reaches the outer

side of external sphincter, the track is dissected by making a buttonhole through the external sphincter, internal sphincter and mucosa. The entire track is thus excised in toto from outside in. If some difficulty is encountered, then the dissection is carried out trans anally. A circular incision is made in the posterior midline surrounding the internal opening. The incision is deepened and should include the indurated nodule containing anal gland. Gentle traction is applied on the externally cored out track. This enables one to dissect out the track from within out. At the end of the complete excision of the track there remains a buttonhole in the mucosa and both the sphincters with a wound in the ischiorectal fossa. The rent in the sphincteric muscles is repaired by horizontal running sutures. This is begun at one corner by taking continuous suture using 2-0 chromic catgut or 3-0 vicryl rapid. After the muscular defect is sutured the mucosal flap is mobilize by undermining its edges. The mucosal flap is sutured to the lower part of the anoderm in a similar fashion. Thus the defect is closed in two layers. Horizontal suturing should be done without any tension so as to prevent the sutures cutting through. If there is lot of fibrosis it may not be possible to close the rent in two layers. In that case a deep bite is taken through the mucosa including the underlying fibrous muscle tissue and the defect is closed in one layer. Thus the outer part of the wound gets disconnected from the anal canal and helps in preventing faecal contamination. The outer wound is packed with a solution containing providone iodine and hydrogen peroxide (Fig. 15).

Postoperatively the outer wound is irrigated daily with the same solution and lightly packed.

High trans-sphincteric fistulae

In this type of anal fistula the track runs

upto the summit of the ischiorectal fossa. The external opening is usually far away, sometimes it may be in the gluteal region or it may be anteriorly, near the root of the scrotum. Some of them may have multiple openings. In all these cases the dye is injected to outline the track. The internal opening in the posterior midline is confirmed by emergence of the dye or by feeling the indurated nodule. The principle of the surgical procedure remains the same. The fistulous track is cored out from the outer opening upto the internal opening by making a buttonhole in both the sphincters and the inner mucosa. Since the external openings are far away it may be necessary to make a counter incision near the outer side of external sphincter and the dissected track is delivered out and then followed up inward or dissected from inside out as sated before in low trans-sphincteric fistula. Care should be taken while dissecting the track to avoid injury to the pudendal vessels since profuse bleeding can occur from the spiriting artery and it may become difficult to locate it. It is advisable to use coagulation current more frequently to cauterize all bleeders and dissect under direct vision only. It is better to catch them with artery forceps, coagulate and then divide to prevent profuse bleeding. If the bleeder cannot be located best thing is to pack the wound, enlarge it, if necessary and then cauterize or underrun.

After excising the entire track the wound must be inspected with the help of retractors and fibre optic cable light or self-illuminated retractor. All the stained tissue and unhealthy tissue must be excised. Sometimes a small tiny looking brown tissue when followed up will lead to another deeper track, which must be currated. Sometimes the track may extend to the opposite site, which should be dissected through the intra anal incision. The bilateral trans-sphincteric fistula or what is called as complete horseshoe fistula is dealt

with in the similar manner. At the end of surgery anal canal is reconstructed by suturing in two layers or one layer as described before. While doing so care must be taken not to create a ridge beyond the suture line near the anal verge. This may result into breakdown of the repair.

Supralevator fistulas are also dealt in the similar manner. The supralevator extension is usually a blind end. It is curved out with the help of scoop or a sharp curate. Any secondary opening in the rectum is closed from outer side after trimming its edges.

Combined intersphincteric and trans-sphincteric anal fistula

The excision of trans-sphincteric part remains same as before. The intersphincteric track is dealt with gentleness and sharp dissection to prevent creating a rent in the anal canal and rectum. The dissection is usually from both sides that is from the outer wound and trans anal wound with a finger in the rectum to provide a guideline during dissection. After the complete excision the anal canal is reconstituted. If the sphincteric defect is large it becomes necessary to put an additional suture from the outer wound on outer part of the external sphincter. A deep bite is taken to suture up the defect from outer side. This is done by taking continuous stitch, which enables to close the defect completely.

Postoperative dressings

It is preferable to prevent bowel movement at least for 48 hours. The dressing is changed after 48 hours. The wound is then irrigated and lightly packed. Dressing must be done after every bowel movement or twice a day at least for one week so as to prevent collection of infected fluid in the external wound. Even if there is break down of sutures the dressing is continued in the same

manner. Due care must be taken to flush out any embedded faecal matter. The irrigation of the cavity is done with the help of enema can. The wound is irrigated with warm boiled water to which providone iodine is added. To make the irrigation more comfortable it is advisable to apply lignocaine jelly in the wound prior to irrigation. It is preferable to do the dressing in lithotomy position as the wound can be visualized properly. For first two weeks dressings must be done or supervised by the operator himself. It takes anywhere from eight to twelve weeks for complete healing to occur. After two weeks if there is exuberant granulation tissue it needs to be scraped under local anaesthesia. If the external part of the wound is closing faster one should enlarge it under local anaesthesia. If in spite of all this wound does not heal there is likely hood of recurrence but one should wait for four to six months before undertaking second surgery.

Surgery of unclassified and complicated anal fistulae

In these types of fistulae the external opening may be in the groin or anywhere in the abdomen either due to subcutaneous spread or through deep perineal pouch. In all these cases an indwelling Foley's catheter is inserted to provide the guide line while dissecting out the track and prevent any injury to urethra. Dye is injected from the external opening. A stiff tube or ureteric catheter is passed from the external opening. Unless the track is tortuous or partially obliterated the catheter can be negotiated upto the internal opening in the anal canal.

If the track is superficial it passes by the side of urethra and usually opens into anus in anterior midline. If the track is lined by granulation tissue it is curved out. If there is lot of fibrosis it is dissected out from its external opening upto its internal opening

into the anal canal by dividing the sphincters. The anal canal is reconstituted by suturing the mucosa and sphincters. The external wound if possible is closed in two layers. The outer layer i.e. skin is closed by interrupted nylon suture. Loose stitches are taken to allow drainage and prevent any collection in the depth of the wound. If urethra is injured it must be repaired. This may necessitate suprapubic cystostomy.

Deep fistulous track

It is usually an extension of supralelevator fistula. This type of track runs behind the pubic ramus, which enters into preperitoneal or retroperitoneal space. It becomes necessary to operate from both sides. A circular cut is made around the external opening in the abdominal wall and the track is cored out as far as possible. The dissection is then carried out from ischiorectal fossa towards its summit and also towards the internal opening into the anal canal. It is difficult to follow the dissection behind the pubic ramus into the preperitoneal space. The segment of the track, which remains between the abdominal dissection and ischiorectal fossa is gently scooped out. Care must be taken to

prevent any injury to major vessels. At the end of surgery anal canal is reconstituted. The wound in the abdomen and ischiorectal fossa is lightly packed. The postoperative dressing is done in the similar manner described before.

In author's experience there was one case in which the abscess had tracked into the deeper plain of the thigh below the attachment of glutei muscles. The track passed behind the greater trochanter and tracked on the lateral side of the thigh under the tensor fascia lata. In this case the track was scooped out from thigh by flexing the hip with internal rotation. The track from posterior internal opening was scooped out through the anal canal. The abdominal part of the track on the opposite side was dealt with as described before.

References

1. Goligher JC. Surgery of the anus, rectum and colon.
2. John R Nicholls, Roger R Dozois. Surgery of the colon and rectum.
3. Philip H Gordon, Santhat Nivatrong. Principles and Practice of Surgery for the Colon, Rectum and Anus.

RESTLESS LEGS SYNDROME

Restless legs syndrome is a common movement disorder and is underdiagnosed and undertreated. It has an estimated prevalence of 10-15% in the general population.

The key feature of restless legs syndrome is an uncontrollable urge to move the legs.

Exercise should be recommended as it ameliorates symptoms. Rubbing the legs and hot or cold bathing (depending on symptoms) may also be useful. Drug therapy is required in only 20-25% of more severe cases. Dopamine agonists are the mainstay of treatment and show benefit in nearly all patients.

The Practitioner, 2008 : 3.