

# Goldenhar Syndrome with Agenesis of Septum Pellucidum

Mona Gajre\*, K Palaniswamy\*\*, Surbhi Rathi\*\*\*, Darshana Rathod\*, Venkatesh Deshpande\*, Mukesh Agrawal\*\*\*\*

## Abstract

Goldenhar syndrome also known as the Facio-Auriculo-Vertebral Spectrum is a morphogenetic anomaly involving the first and second branchial arches. It has a varied spectrum and in 70% unilateral involvement of the face, ear and vertebral systems is seen. It is known to be accompanied with ocular and renal anomalies.

## Introduction

The Goldenhar syndrome (Facio-Auriculo-Vertebral Spectrum, First and Second Branchial Arch Syndrome, Hemifacial Microsomia), is a morphogenetic anomaly first described by Von Arlt in 1845 but defined clearly by Goldenhar almost a century later.<sup>1</sup> It consists of pre auricular appendages, hypoplastic or absent pinnae, epibulbar dermoid, microphthalmia, hypoplasia of malar, maxillary or mandibular region, macrostomia, cleft palate, hemi-vertebrae and other vertebral anomalies.

## Case Report

A 6-month female of non-consanguineous marriage presented with history of left corneal opacity since birth and absence of right external auditory meatus. The antenatal period was uneventful and the family history insignificant. On clinical examination the following was seen (Fig. 1) a. *facial features*: flat nasal bridge, right sided – deviation of angle of mouth, hypoplasia of facial muscles especially depressor anguli oris, hypoplasia of the right mandible. b. *ears*: right microtia, bilateral preauricular skin tags. c. *eyes*: left microphthalmos with epibulbar dermoid and corneal opacity. d. *spine*: hemivertebra of third thoracic vertebra. Systemic examination did not

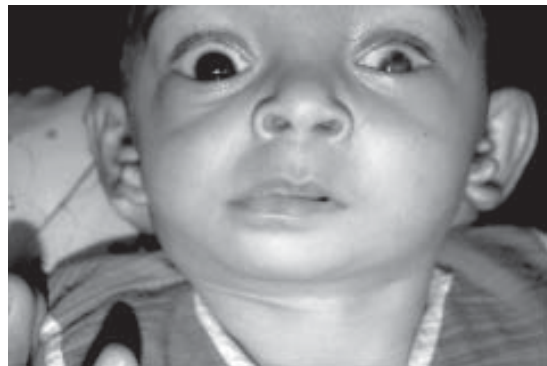

Fig. 1: Goldenhar syndrome showing marked facial asymmetry, malformed ears, pre-auricular tags, left corneal opacity with epibulbar dermoid.

reveal any cardiovascular or renal abnormality.

**Investigations** : X-ray spine showed hemivertebra of third thoracic vertebra. CT brain revealed absence of septum pellucidum, hypoplasia of corpus callosum with squared off frontal and temporal horns of lateral ventricle (Fig. 2) and mild non-communicating hydrocephalus. 2DECHO and ultrasound abdomen were normal.

## Discussion

The Facio-Auriculo-Vertebral Spectrum is a defect of the structures arising from first and second branchial arches that is involvement of the vertebral, renal and ocular systems. Earlier Goldenhar syndrome was described as the presence of epibulbar dermoid with vertebral anomalies whereas

\*Lecturer; \*\*Registrar; \*\*Associate Professor; \*\*\*\*Professor and Head of Unit, Department of Paediatrics and Ophthalmology, TN Medical College and BYL Nair Hospital, Mumbai 400 008.

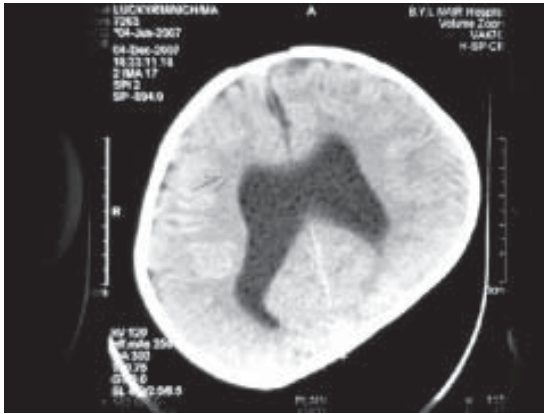


Fig. 2 : CT brain reveals hypoplasia of corpus callosum with squared off frontal and temporal horns of lateral ventricle and mild non-communicating hydrocephalus.

predominant unilateral occurrence was termed as hemifacial microsomia.<sup>1</sup> Recently however all of the above are thought to be variable manifestations of a similar error in morphogenesis. In fact in a recent report polydactyly and hydrocephalus have also been described as associations.<sup>2</sup>

The exact aetiology of Goldenhar syndrome is not known but is believed to be due to abnormal embryonic vascular supply to the first arch affecting the formation of branchial and vertebral systems. The incidence of Goldenhar syndrome is 1:3000 to 1:5000 with a male to female ratio of 3:2. Estimated recurrence in first degree relatives is 2% although minor features may be seen in relatives. Maternal diabetes may be seen in some cases.<sup>3</sup>

The spectrum describes asymmetry and unilateral facial features such as hypoplasia of malar, maxilla, mandibular region, lateral cleft like extension of the corner of the mouth (macrostomia), hypoplasia of depressor anguli oris in 70% of cases. Ear anomalies occur in 40% and include microtia, preauricular tags, pits mostly in a line from the tragus to the corner of the mouth. Incidence of

hemivertebrae or hypoplasia usually of the cervical vertebra is reported to be 40-60%. Ocular anomalies especially epibulbar dermoid, notch in the upper lid, microphthalmia are seen in 60% of cases. Occasional abnormalities are acyanotic heart lesions, ectopic or fused kidneys, laryngeal anomalies, hydrocephalus, encephalocele, agenesis of corpus callosum, calcification of falx cerebri, hypoplasia of septum pellucidum, radial or rib anomalies.<sup>3</sup> Mental deficiency is more common with microphthalmia.

The syndrome has to be differentiated from Treacher-Collins syndrome, Pierre Robin syndrome, Moebius syndrome and thalidomide embryopathy. However these conditions have their own distinguishing features such as marked mandibular hypoplasia in Pierre Robin syndrome, sixth and seventh nerve palsies in Moebius syndrome and phocomelias in thalidomide embryopathy.

Treatment is aimed at cosmetic repair of the eyes and ears and should be postponed till growth of the structures is completed. The epibulbar dermoid can regrow and recurrences are seen even 12 year after original surgery. Orthodontic treatment may be required for maloccluded teeth, hearing aids in conductive hearing loss.

#### Acknowledgement

We thank our Dean Dr. SN Oak for granting permission to publish this case report and the Department of Ophthalmology for their kind co-operation.

#### References

1. Goldenhar M. Associations malformatives de l'oeil et de l'Oreille. *J Genet Hum* 1952; 1 : 243-82.
2. Oculo-Auriculo-Vertebral Spectra of Defects. In Smith's Recognisable Patterns of Human Malformation. Jones KL, 6<sup>th</sup> edn, WB Saunders Company, Philadelphia, pg 738-39.
3. Kumar R, Balani B, Patwari AK, Anand VK, Ahuja B. Goldenhar syndrome with rare associations. *Indian J Ped* 2000; 67 : 231-33.