

# Localised Amyloidosis of The Urinary Bladder

Vinaya B Shah\*, Hemant R Pathak\*\*

## Abstract

Amyloidosis is a heterogeneous group of disorders affecting a single-or multiple-organ system and presents as generalized or localized disease. Which can be primary or secondary. Localized amyloidosis affects organs like urinary bladder, lung, larynx, skin and tongue, producing detectable nodular masses which are clinically suspected as malignancy. A case of primary amyloidosis of the urinary bladder is reported. This is a rare clinical entity and is of interest to the urologist because it is usually confused with carcinoma clinically and cystoscopically and histological examination is a must for definite diagnosis and proper management.

## Introduction

Amyloidosis is a heterogeneous group of disorders affecting a single-or multiple-organ system and presents as generalized or localized disease. Primary localized amyloidosis is a rare. This condition is of clinical interest because in symptoms and gross appearances, it resembles neoplasm. Accurate diagnosis depends on the biopsy of the lesion. We present a case of localized amyloidosis of urinary bladder that was clinically and cystoscopically suspected as bladder tumour.

## Case Report

A 27 year-old male patient presented with complaints of intermittent, painless haematuria since 3 months. He has bronchial asthma since last 20 years. Urine analysis showed no other feature but numerous RBC's per high power field. His haemoglobin was 10.5 gm%. TLC, DLC and blood biochemistry for renal functions were within normal limits. Cystoscopy revealed a 2 x 3 cm sized, solid, nodular, circumscribed mass arising from the bladder base on the posterior wall. A provisional diagnosis of carcinoma bladder was made and a transurethral resection of the lesion was performed.

\*Associate Professor, Department of Pathology;  
\*\*Professor and Head, Dept. of Urosurgery, TN Medical College and B Y L Nair Hospital, Mumbai.

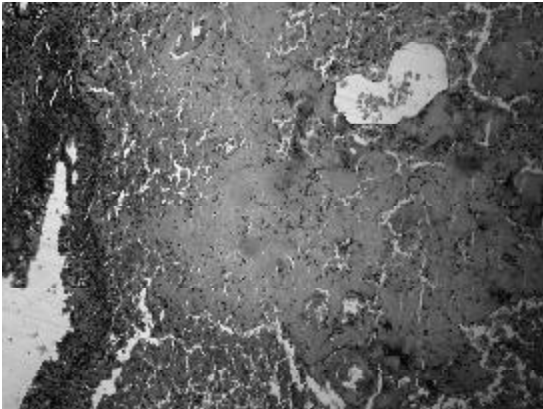
On histopathology, there were massive deposits of structureless eosinophilic material in the sub-epithelial region (Fig. 1). On congo red staining, the material exhibited the classical apple-green birefringence under polarised light (Fig. 2).

Subsequently, the case was investigated for the evidence of systemic amyloidosis. These included urine for Bence-Jones protein, serum protein, serum electrophoresis, liver function tests, VDRL, creatinine clearance, radiologic survey of spine, skull and ribs, sternal marrow biopsy and rectal biopsy. All were negative for amyloidosis.

## Discussion


Amyloidosis of the bladder is a rare condition which often mimics bladder neoplasm clinically and cystoscopically and histological examination is a must for definite diagnosis and proper management.

Amyloidosis encompasses a heterogeneous group of disorders which are characterized by extracellular deposition of eosinophilic fibrillar protein in various tissues and organs. In the urinary tract, deposition of amyloid can occur anywhere, starting from kidney to renal pelvis. The kidney is nearly always involved in secondary amyloidosis and in approximately 50% of the cases of primary amyloidosis. This is in contrast to the urinary bladder, which is usually affected in primary localized amyloidosis.<sup>1,2</sup> Most cases of vesical



*Fig.1 : H & E stained section of bladder shows urothelium, von Brun's nest and extensive eosinophilic masses of amyloid within lamina propria.*

amyloidosis appear to be of primary type-the so-called "tumour-forming" amyloidosis. The aetiology of this type of amyloidosis is unknown. The bladder wall is thickened and mucosa is hyperaemic, rough, nodular with small ulcerations which simulate sessile carcinoma on cystoscopy. Histologically, amyloid deposit is typically amorphous and more or less homogeneous. It is mainly seen in and between the collagen fibres of lamina propria but can extend into the muscularis. There is predilection for involvement of the media of arteries and veins. Muscle cells are replaced by amyloid material. Polarization of amyloid stained with Congo red gives apple-green birefringence. Amyloidosis is a rare cause of irritative voiding symptoms and haematuria and presents as an uncommon differential diagnosis of urinary bladder carcinoma. Primary amyloidosis localized to the urinary bladder is quite rare.<sup>3</sup> Patients usually present with gross haematuria, irritative voiding symptoms, or both. Localized amyloidosis poses a diagnostic problem because of its nonspecific presenting symptoms and nodular cystoscopic appearance, which may mimic inflammatory



*Fig. 2 : Congo red slide under polarizing microscope showed apple green birefringence exhibited by the amyloid deposits.*

lesion or a neoplastic lesion. Histopathological examination is necessary to confirm the diagnosis of amyloidosis and to exclude malignancy. Primary systemic amyloidosis is usually not accompanied by lower urinary tract symptoms, whereas primary localized bladder (tumour-forming) amyloidosis is almost always accompanied by such clinical features.<sup>4,5</sup> The incidence of gross haematuria has been reported to be 58% to 77% and irritative voiding symptoms have been reported in 23% of cases in different studies.<sup>4,5</sup> Since clinical, radiological and cystoscopic features closely simulate bladder malignancy, it is not possible to establish a correct diagnosis of amyloidosis except by histopathological study of the biopsy from the vesical lesion. Therefore, a clinically suspicious negative cystoscopic bladder biopsy should be cautiously evaluated for the presence of amyloidosis and histologically suspected cases of amyloid should be subjected to congo red staining.

#### **References**

1. Goswami AK, Vaidyanathan SS, Rao MS. Primary localized amyloidosis of urinary bladder: A case report. *J Postgrad Med* 1984; 30 : 253-4.
2. Jain M, Kumari N, Chhabra P, Gupta RK.

- Localized amyloidosis of urinary bladder: A diagnostic dilemma. *Indian J Pathol Microbiol* 2008; 51 : 247-9.
3. Ferch R, Haskell R, Farebrother T. Primary amyloidosis of urinary bladder and ureter. *Br J Urol* 1997; 80 : 953-4.
  4. Tirzaman O, Wahner-Roedler DL, Malek RS, Sebo TJ, Li CY, Kyle RA. Primary localized amyloidosis of the urinary bladder: A case series of 31 patients. *Mayo Clin Proc* 2000; 75 : 1264-8.
  5. Khan SM, Birch PJ, Bass PS, Williams JH, Theaker JM. Localized amyloidosis of the lower genitourinary tract: A clinicopathological and immunohistochemical study of nine cases. *Histopathology* 1992; 21 : 143-7.

#### **ANTIRETROVIRAL THERAPY : TOXICITY AND ADHERENCE**

Today, India has the third highest HIV burden in the world with an estimated 2.5 million people living with HIV in 2006 with an adult HIV prevalence approximately 0.36%.

After ART became available HIV-AIDS no more sounded like a death sentence to the patient, it rather transformed into a manageable ailment. The advent of such highly active antiretroviral therapy (HAART) sharply brought down AIDS related mortality levels and improved quality of life. Before the availability of antiretroviral therapy, median survived after diagnosis of AIDS was 12 to 18 months.

NACO supplies fixed drug combination of zidovudine, amivudine, stavudine (nucleoside reverse-transcriptase inhibitors, NRTI), nevirapine and efavirenz non-nucleoside reverse transcriptase inhibitor. NNRIU in free ART programme.

Compliance to ART is one of the major areas of concern in management of HIV/AIDS patients especially in view that it is a lifelong treatment.

It must be stressed that majority of patients are able to tolerate HAART well, even over years. The monitoring of treatment toxicity by an HIV clinician is recommended in at least three monthly intervals, even in asymptomatic patients, and more often at the beginning of a new HAART, when it should be weekly or fortnightly. Routine investigations include a full blood count, liver, pancreas and renal function tests, electrolytes as well as fasting cholesterol, triglycerides and glucose levels.

The commonest adverse drug reaction (ADR) reported by them was rash due to Nevirapine. Other ADRs in their study were peripheral neuropathy (PN) in 22.2% and anaemia in twenty per cent. Another study from South India by Kumarasamy *et al* reported a 15.2% incidence of rash, 9% incidence of PN, 5.4%, anaemia and 3.5% hepatitis.

Lactic acidosis develops late in patients in HAART.

Apart from the acute toxicities. HAART can lead to delayed toxicity in the form of morphologic and metabolic complications like lipodystrophy, dyslipidaemia, osteo-necrosis and osteopenia as well.

Treatment of HIV infection has become a complicated balancing act between the benefits of durable HIV suppression and the risks of drug toxicity. The newer additions in the NRTI class like Tenofovir, Abacavir offer some such options. Introduction of these drugs will improve compliance thereby decreasing the incidence of drug resistance. Protease inhibitors (PIs) the other class of ART as a part of second-line regimen, in free ART programme also need consideration when NNRTI use is not possible.

**Milind Y Nadkar, Smrati Bajpal. J Assoc Physician India, 2009; 275 : 375-76.**