

Subclinical Keratoconus

Nita Umesh Shanbhag*, Swapnesh Deepak Sawant**, Pooja Anil Deshmukh***

Abstract

A 21 year old male presented as forme fruste keratoconus by chance during the pre-op evaluation of Lasik procedure. He desired to correct a refractive error of -1.5 D for procuring a job in Defence Academy. The criteria for recruitment is unaided vision of 20/25. A low spherical refractive error with no astigmatic component never raises a clinical suspicion of ectasia. Orbscan prior to Lasik, documented a posterior elevation greater than 50 microns above the Best Fit Sphere (BFS). This fitted into Keratoconus suspect. Any preexisting tendency to ectasia like keratoconus will be manifested and aggravated by kerato-refractive surgeries. This case is presented to increase the index of suspicion of general ophthalmologist. Referral to corneal consultants at this stage will improve chances of maintaining good vision with help of corneal collagen cross linkage (C₃R) in case of progressions.

Introduction

Lasik in situ keratomileusis involves removal of corneal tissue which makes it flatter and thinner. It is important to diagnose these cases of sub-clinical keratoconus to prevent iatrogenic keratectasia. The orbscan is unique in its ability to assess the true elevation of the cornea not only on its anterior surface but also on its posterior surface.^{1,2} Posterior corneal elevation very effectively discriminates keratoconus from normal corneas. Its efficacy is lower for subclinical keratoconus, thus data should not be used alone to stratify this condition.³

Case History

A 21 year old patient came to our OPD with the sole desire to get rid of his glasses. He had applied for a job in defense academy and their criteria for selection was unaided vision of 20/25. He wore glasses for the last five years with constant refractive error of -1.25 D. He gave no history of contact lens wear. On evaluation for Lasik, he accepted -1.5 D without

cylinder in both eyes. His left eye clarity was better than his right eye. Fundus was normal. Intraocular pressures were 14 mm both eyes. Mesopic pupil was approximately 5.0 mm. Basic Schirmer's test was 25 mm. Ultrasound Pachymetry both eyes was less than 500 microns. The thinness of the cornea raised our suspicion level and patient was referred for an orbscan, which showed forme fruste keratoconus (Figs. 1 and 2). Orbscan is known to over-diagnose posterior corneal elevation. This patient at 4 months documented a progression of refractive error to -2.0 D in the right eye though his left eye remained at -1.5 D. The Orbscan picture showed progression and thinning in the right eye whereas left eye remained the same (Table 1).

We did not suspect forme fruste keratoconus earlier, as patient was asymptomatic. Being a small refractive error we did not dilate the pupil. Dilated retinoscopy did show a difference of 1 D between the two meridians but no scissor shadows. In the Orbscan, the posterior float lies completely within the central 3 mm zone. A little eccentricity may have helped us pick up an astigmatic error which could have upped our level of suspicion. The orbscan came to our rescue though it is not feasible to do this test in every patient.

This case is sent for publication to increase awareness among the general ophthalmologists. The criteria of suspect keratoconus may not necessarily yield a high sensitivity and specificity. A simple case like this where, had the patient not insisted on lasik we would not have done his pachymetry or orbscan

*Head and Professor; **Registrar; ***Lecturer; Dept of Ophthalmology; D.Y. Patil Medical College and Research Center, Nerul, Navi Mumbai.

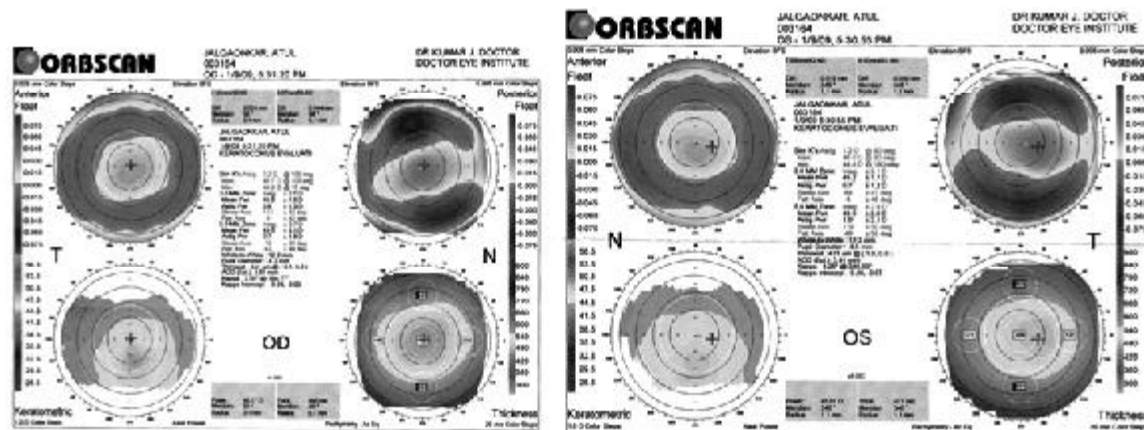


Fig. 1 : BES Orbscan showing posterior corneal elevation depicting Forme Fruste Keratoconus.

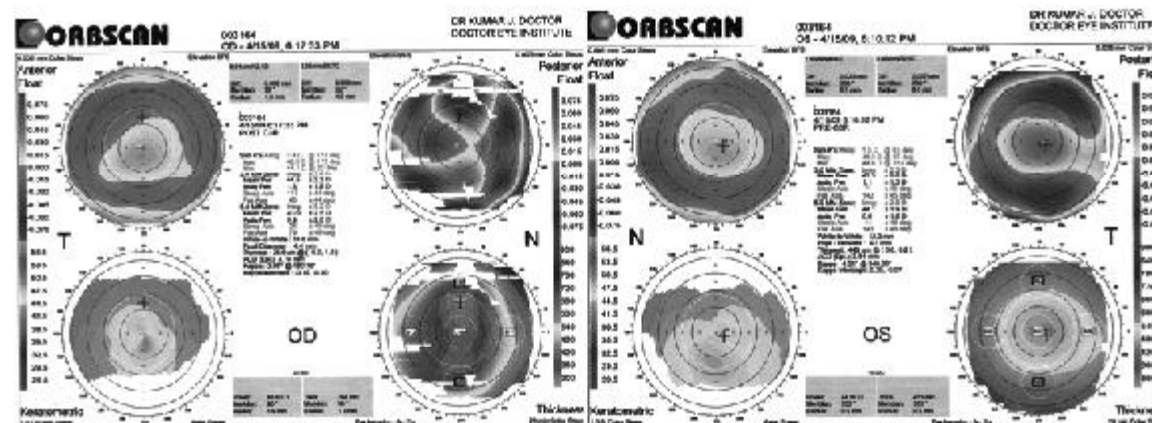


Fig. 2 : BES Orbscan showing Right eye progression and thinning with Left eye no change.

and he would have progressed with deterioration in visual acuity. Today we have C₃R which helps us in stopping the progression of the disease. We did not find the need to go ahead and do aberrometry which detects these cases much earlier, as orbscan had already picked up a posterior elevation. However in a patient who complains of unequal clarity of vision even though patient reads 20/20, it would be worthwhile doing an aberrometry and orbscan as it may help us pick up an early forme fruste keratoconus. This patient underwent a C₃R subsequently for his right eye.

Discussion and Review of Literature

Keratoconus suspects and contact lens induced warpage resembling keratoconus are present in the “normal” myopic population that presents for refractive surgery.

Videokeratographic screening is the only effective means of identifying these and other corneal shape abnormalities.⁴ Patients with positive keratoconus screening tests have higher anterior and posterior elevation on Orbscan topography. In combination with videokeratography it may help in identifying patients at high risk for developing ectasia after Lasik.⁵

Signs suggestive of an early keratoconus on Corneal Topography (Orbscan)

Pachymetry

A thinnest point of < 470 microns

Table 1 : Comparative chart between Keratoconus Suspect and our case

	Keratoconus suspect	Case - RE	Case - LE
Refraction especially the cylindrical component.	> 1 D between the 2 eyes is suspect	-1.5 D progressed to -2.0 D	-1.5 D
Retinoscopy in dilated pupil.	Scissor shadows	Nil	Nil
Radius of Anterior corneal curvature.	> 7.35 mm/46 D	7.93 mm/42.6 D	7.89 mm/42.8 D
Radius of Posterior corneal curvature.	> 6.5 mm/52 D	6.37 mm/53 D	6.5 mm/51.9 D
Ratio of Anterior/Posterior corneal curvature.	> 1.23 to 1.27	1.245	1.214
Posterior best fit sphere.	> 52 D	53 D	52 D
Elevation of the posterior corneal surface above the posterior best fit sphere.	> 45 microns	55 microns	45 microns
Total mean Keratometric power map.	> 46 D	46.17 D	45.2 D
Infero-temporal displacement of the highest point on anterior as well as posterior elevation profile.	Posterior float relation to the central 3mm.	Complete posterior float within the central 3 mm	Complete posterior float within the central 3 mm
Thinnest point of cornea.	< 470 microns	444 microns	471 microns
A difference in pachymetry from the thinnest point to the values of the 7 mm OZ	> 100 microns	143 microns	117 microns
Astigmatism between the two eyes.	> 1.5 D in the 3 mm zone and a discrepancy of > 2 D in the 5 mm zone	3 mm OZ - 2.1 D 5 mm OZ - 2.7 D	3 mm OZ - 2.1 D 5 mm OZ - 2.9 D
Skewing of the radial axis.	Bow-Tie pattern or lazy C on the axial power map is suspect when the astigmatism shifts > 20 degree from a straight line	Steep Axis: 112 degree Flat Axis: 8 degree	Steep Axis: 84 degree Flat Axis: 6 degree

A difference of > 100 microns from the thinnest point to the values of the 7 mm Optic Zone implies a steep gradient of thinning from mid-periphery to the thinnest point.

The thinnest point on the cornea should correspond with the highest point of elevation of the posterior corneal surface.⁶

Posterior elevation map

A posterior high point > 50 microns above BFS.

A BFS with a power > 55 D on the posterior profile

Roush criterion: A relative difference > 100 microns between the highest and lowest point on the posterior elevation map.⁶

Power map

Keratometric mean power map > 46 D

Bow-Tie pattern or lazy C on the axial power map is suspect when the astigmatism shifts > 20 degree from a straight line.

A change within the central 3 mm optic zone of the cornea of more than 3 D from superior to inferior can be correlated to the presence of vertical coma (commonest

aberration seen in keratoconus).⁶

Composite integrated information

Highest point on the posterior elevation coincides with the highest point on the anterior elevation, the thinnest point on pachymetry, and the point of steepest curvature on the power map

Efkarpides criteria: Ratio of the radii of the anterior BFS and posterior BFS of the cornea should be more than 1.21. Between 1.23 and 1.27 would be suspect and > 1.27 is diagnostic.

Astigmatic discrepancy of > 1.5 D in the 3 mm zone and a discrepancy of > 2 D in the 5 mm zone should be an alert sign.⁶

Forme fruste keratoconus presents with no slit-lamp findings or scissoring on retinoscopy, but the typical topography findings. Normal corneas tend to be symmetrical, hence asymmetry is a clue to pathology. The pattern of an asymmetric bow-tie with a skewed radial axis only occurs in 0.05% of the normal patient population, but is universal in patients with keratoconus. Such individuals, even in the absence of clinical evidence of keratoconus, should be treated with a high degree of suspicion. A combination of an abnormal inferior/ superior value with high vertical coma on wavefront analysis should be treated as high risk.⁷ Topographic systems may be a useful tool in the study of true incidence and natural progression of sub-clinical keratoconus.⁸

Dr. Bühren found differences in the pattern of corneal higher order aberrations (HOA) between clinically inconspicuous fellow eyes of keratoconus patients and the normal

control eyes for the coefficients Z1-1 and Z3-1 and for the RMS value of total HOA. In keratoconic eyes, the dominant wavefront error is vertical asymmetry (coma). Thus aberrometry could be the clue to early diagnosis in cases of high index of suspicion.⁹

References

1. Rabinowitz YS. Keratoconus. *Surv Ophthalmol* 1998; 42 : 297-319.
2. Seiler T, Quurke AW. Iatrogenic Keratectasia after Laser In Situ Keratomileusis in a case of Keratoconus. *J Refract Surg* 1998; 24(7) : 1007-9.
3. De Sanctis U, Loiacono C, Richiardi L, Turco D, Mutani B, Grignolo FM. Sensitivity and specificity of posterior corneal elevation measured by Pentacam in discriminating keratoconus/ subclinical keratoconus. *Ophthalmology* 2008; 115(9) : 1534-9.
4. Nesburn AB, Bahri S, Salz J, Rabinowitz YS, Maguen E, Hofbauer J, *et al.* Keratoconus detected by videokeratography in candidates for photorefractive keratectomy. *J Refract Surg* 1995; 11(3) : 194-201.
5. Rao SN, Raviv T, Majmudar PA, Epstein RJ. Role of Orbscan II in screening keratoconus suspects before refractive corneal surgery. 2002; 109(9) : 1642-6.
6. Agarwal Sunita, Agarwal Athiya, Agarwal Amar. Dr Agarwals Textbook on Corneal Topography, 1st edition, Jaypee Publications 2006.
7. Yaron S, Rabinowitz. Diagnosing Keratoconus and Patients at Risk. *Cataract and Refractive Surgery* 2007 : 85-87.
8. Maguire LJ, Lowry JC. Identifying progression of subclinical keratoconus by serial topography analysis. *Am J Ophthalmol* 1991; 112(1) : 41-5.
9. Bühren C, Kühne T, Kohnen. Defining Subclinical Keratoconus Using Corneal First-Surface Higher-Order Aberrations. *Am J Ophthalmol* 2007; 143(3) : 381-9.