

Eye Signs in Tuberculosis

HL Trivedi*, Ramesh Venkatesh**

Introduction

Tuberculosis is very common in India and hence it is very essential for the general practitioners treating patients to be aware of the eye signs of tuberculosis for early detection and timely treatment to prevent complications which can lead to blindness.

TB Conjunctiva

- Extremely rare
- May occur as primary tuberculous conjunctivitis or due to secondary infection

Primary TB conjunctivitis

- Usually unilateral, age < 20 yrs, M < F.
- Mode of infection- exogenous, following injury or abrasion to the conjunctiva which permits the entry of bacilli.
- Onset – slow
- Characterized by lacrimation, mucoid secretion and conjunctival and lid oedema, with swelling and caseous pre auricular and sub maxillary LN. Conjunctiva becomes hypertrophied and large follicles appear which may break down and ulcerate.
- Course – chronic
- Healing is by conjunctival scarring or spread to the underlying tissues or surrounding structures.

Secondary TB conjunctivitis

- Bilateral, age > 20 yrs, previously infected pts.

*Associate Professor; **Resident, Department of Ophthalmology, BYL Nair Charitable Hospital.

Reprinted from : BHJ 2008; 50 (2) : 258-63

- Results due to the infection of the conjunctiva from a contagious TB focus- TB lid, tarsus, orbit, lacrimal gland.
- No associated LN enlargement.
- May present in any 1 of the 6 forms:
 1. Small millet seeded ulcers which may or may not coalesce
 2. Small grayish sub conjunctival tubercles
 3. A hypertrophic form, with proliferative changes and large cockscomb excrescences.
 4. Pedunculated polyps arising from the tarsal or fornicial conjunctiva.
 5. Lupus conjunctiva associated with lupus of the skin.
 6. Tuberculoma of the conjunctiva.

Phlyctenulosis

- Allergic response to the Myco. TB
- Typically, phlyctenulae are seen in children
- On the bulbar conjunctiva, adjacent to the limbus. They may also occur on the cornea near the limbus independently or as an extension of a conjunctival extension.
- A leash of blood vessels may extend from the conjunctiva to the cornea giving the so-called fascicular keratitis.
- Photophobia, conjunctival injection and lacrimation are common symptoms. The child keeps his lids closed and tries to seek dark corners.
- Within 2-3 days the small greyish masses break down, small pits appear at the apex, the phlyctenules sink to the level of the conjunctiva and quickly epithelise over.

- They are often not solitary.
- Recurrences are very common.
- If cornea is not frequently involved and in depth, there is no scarring; full recovery occurs.
- Secondary infection may occur.
- Decreased vision may be due to dense corneal scarring with pannus.
- Corneal perforation is a very rare complication (Fig. 1).

TB Cornea

Sclero keratitis

- Marginal keratitis with involvement of the contiguous sclera.
- Arise either as an extension of TB scleritis to the cornea or from the bacilli from the Schlemm's canal producing corneal lesions which secondarily involve the adjacent sclera.
- Initially there is deep, vascular congestion at the limbus followed by the appearance of corneal infiltrates. This localized inflammation may later become intense.
- The attack may heal by corneal scarring or may progress to severe keratitis or kerato-uveitis and produce blindness (Fig. 2).

TB interstitial keratitis

- May extend from sclero-keratitis or progression of disease from uveal focus.
- Gradual onset with slow involvement of the cornea, involving the lower 2/3rd.
- Peri-corneal inflammation-mild to moderate.

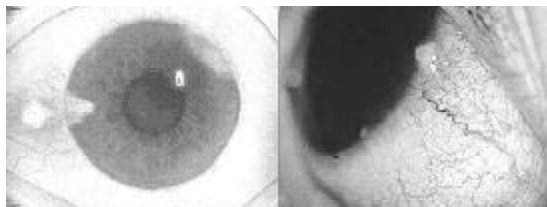


Fig. 1

- Diffuse corneal infiltrates with intracorneal nodules – real tubercles.
- Characteristic superficial vascularisation with occasional deep vascularisation as well.
- Prolonged course with frequent exacerbation and remissions.
- Healing is by scarring or calcareous degeneration of the cornea causing loss of vision.

Deep central keratitis

- Arise from the bacilli in the aqueous which penetrate the corneal endothelium, Descemet's membrane and parenchyma of the cornea.
- Infiltration confined to the deep layers of the central cornea, which gradually spreads to the upper and middle layers leaving a marginal peripheral area clear.
- Corneal sensations +++
- Characteristic deep vascularisation which may proceed to superficial layers in the late stages.
- Healing is by scarring or calcareous degeneration of the cornea leading to blindness.

TB infiltrates of the cornea

- Seen in older age groups.
- Appear as small, localised, whitish

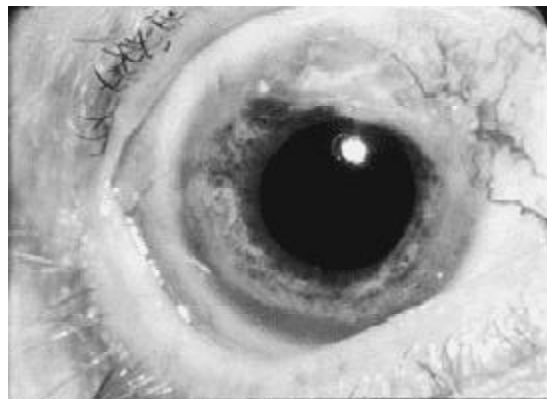

Fig. 2

infiltrates with ill-defined borders and often an opaque halo which merges into clear cornea.

- These infiltrates may either undergo necrosis, ulceration and sloughing or healing by severe scarring with loss of vision (Fig. 3).

TB corneal ulcers

- Extremely rare condition.
- Progressive, relentless and destructive ulcer extending from the limbus with sloping edges and have a caseous base.
- TB bacilli are found in the scrapings.
- Secondary infection of the ulcer is common.
- Ulcer may progress and perforate the cornea leading to loss of vision (Fig. 4).

TB Sclera

- May cause episcleritis or scleritis
- Episcleritis is rare due to hypersensitivity to the Tuberculo – protein.
- Myco. TB most commonly causes deep scleritis- anterior and posterior both.

Anterior Scleritis

- Most frequent type
- Appears as a deep, purplish-red congestion which does not fade on the injection of ephedrine into the conjunctival sac. Involves characteristically 1 sector of the sclera.



Fig. 3

- In the malignant form, there is brawny scleritis, a diffuse, succulent oedematous inflammation of both the sclera and episclera, extending backward to the equator and extra ocular movements. Marginal cornea may be secondarily involved.
- Persists for years and is usually painless.
- Healing is by scarring or the diseased sclera becomes weak to form a localised ectasia.
- Scleral perforation does not occur.

Posterior scleritis

- Affects the sclera posterior to the equator + Tenon's capsule = sclero-tenonitis.
- Characterised by lid oedema, little or no anterior inflammation, mild-moderate proptosis and decreased eye movements.
- Moderate pain during the acute stage of tenonitis.
- Proptosis and ocular immobility disappear as the secondary tenonitis fades (Fig. 5).

TB uveal tract

- A TB focus in the uveal tract may probably be the starting point from which all the other types of endogenous ocular TB arise.
- Mode of spread = haematogenous spread.
- Both the Anterior and the posterior uvea may be involved independently and may

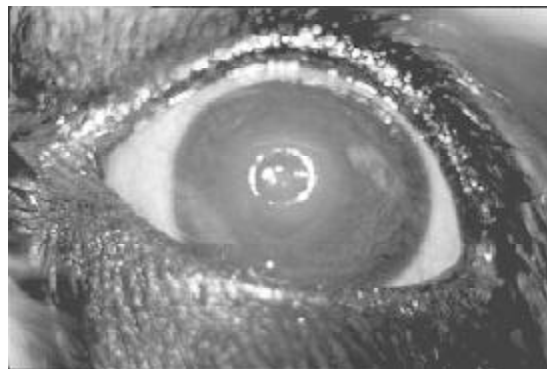

Fig. 4

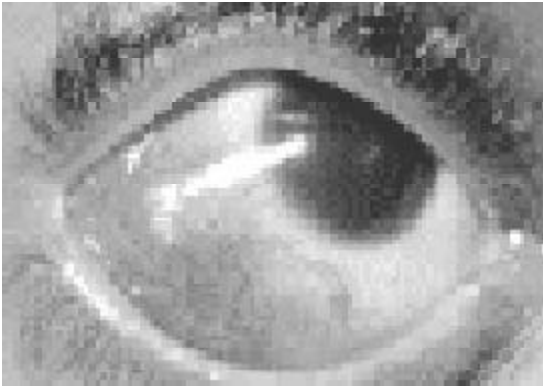

Fig. 5

spread in either direction.

Anterior TB Uveitis

Tuberculous granulomatous uveitis

- Slow onset
- Degree of the initial inflammation parallels the degree of systemic hypersensitivity of the individual.
- Peri-corneal congestion, thickened iris, loss of normal iris pattern and iris lustre, severe post. Synechiae, mutton-fat KPs, presence of the Koeppe's nodules at the pupillary margin.
- Disease to spread backwards to the ciliary body with exudates in the vitreous chamber.
- Capsular clouding of the lens and secondary glaucoma occurs.

Nodular Tuberculous Iritis

- Characterized by miliary tubercles on the iris.
- Occur in pts with low sensitivity to tuberculin and usually with other evidences of miliary tuberculosis.
- Insidious onset with minimal inflammatory and subjective symptoms.
- Tubercles appear as small greyish nodules, either in the superficial iris or in the iris stroma with little surrounding inflammatory reaction surrounded

shortly by a network of fine capillaries which tend to pass over and around the tubercle and invade the surrounding iris stroma.

Conglomerate tubercle of the iris

- Rare condition
- Results either from a forward extension of ciliary tubercle or from the fusion of miliary tubercles
- Appears as a large, invasive malignant tumour located at the angle of the AC. Grows rapidly, invades the cornea and characterised by necrosis, caseation and finally by the perforation of the globe.
- Pain is constant
- Secondary glaucoma occurs early.
- Very poor prognosis
- Enucleation is considered as a merciful procedure.

Posterior TB uveitis

Circumscribed choroiditis

- Usually affects the individual above 20 yrs of age
- Has a predilection for the posterior segment of the eye and tends to involve the macula.
- Initially there is a ill defined lesion in the posterior pole of the eye with decreased vision corresponding to the site of the lesion
- In 6 weeks, the lesion becomes more well defined, does not spread, becomes circumscribed and evidences of healing appear with pigment around the lesion and secondary gliosis.
- Within 3-4 months the lesions appear healed.
- Recurrences are frequent, appear at the periphery of the old lesion and frequently the scars of repeated lesions can be clearly distinguished.

Spreading choroiditis

- Devastating form of choroiditis seen in below 20 yrs having high sensitivity and low immunity.
- Characterised by rapid inflammation and exudations, starting as a small focus spreading over the entire fundus and overlying retina.
- There is clouding of the vitreous and decreased vision.
- Necrosis and caseation always occur
- Finally, there is wide spread atrophic choroiditis, with pigment heaping, gliosis of the choroid and retina and exposure of the choroidal vessels.

Miliary TB of the Choroid

- Frequently seen as a terminal complication of the TB meningitis.
- Tubercles are multiple, 1-3 or more in number, appear as small yellowish- pink nodules with little or no evidence of surrounding inflammation.
- Characteristically seen in the posterior pole of the eye (Fig. 6).

Solitary tubercles of the Choroid

- Seen in adults having low sensitivity and high immunity, affecting the posterior pole of the perifoveal region
- Appear as pearly-white or greyish masses from 1-2 DD in size, well defined and elevated from 1-2 D.
- Little or no vitreous clouding is seen.
- Tubercles usually heal by hyalinization, having an elevated sharply circumscribed mass in the fundus.
- Occasionally, the inflammatory reaction may become intense and a conglomerate tubercle of the posterior segment may form.

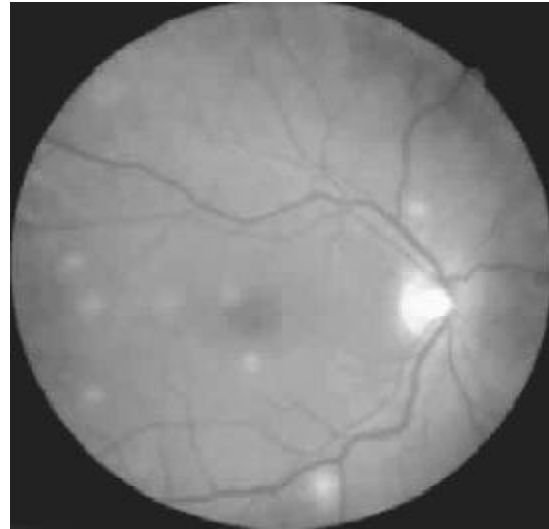

Fig. 6

Conglomerate tubercle of the posterior segment

- Extremely rare, resulting either from the break down of a solitary tubercle and an extension of the inflammation or by the fusion of the miliary tubercles or from an extension of a spreading tuberculous choroiditis.
- Clinical picture is stormy with secondary iritis and acute secondary glaucoma.
- The tuberculoma appears as a large mass covered with exudate and haemorrhages, retina becomes detached and vitreous clouding is present.
- Necrosis and caseation are rapid.
- Perforation of the globe occurs either anteriorly in the neighbourhood of the ciliary body or posteriorly near the equator where the sclera is weakened by the passage of vortex veins.

TB retina

- Usually secondary to choroidal TB
- 2 forms are recognised:
 1. Superficial multiple or single exudates in the retina

2. TB periphlebitis

Exudative retinitis

- Mode of spread - haematogenous spread through the retinal circulation or through a ciliary tubercle rupturing into the vitreous with a seeding out of the bacilli on the retina.
- Usually seen in adults having low-moderate tuberculin hypersensitivity.
- Clinical picture shows superficial, multiple rather circumscribed exudates lying in the retina proper

TB periphlebitis

- Most frequent cause of Eales' disease
- On fundus examination, there is perivascular exudates with massive haemorrhage along one of the retinal veins.
- The repeated vitreous haemorrhages result in cicatricialglial bands. The contraction of these bands ultimately result in retinal detachment and blindness.

TB Optic nerve

TB optic neuritis

- Seen as a complication of TB meningitis in 10-60% of the cases.
- Seen as a result of an extension of the tuberculous inflammation from the meninges to the sheaths of the optic nerve.
- Tubercles are found along the pial coat and may even be present along the intraseptal pial extensions into the nerve substance.
- Necrosis and caseation follow with complete destruction of the nerve occurs ultimately leading to complete optic atrophy and blindness.
- TB optic neuritis may occur following retinal periphlebitis as well (Fig. 7).

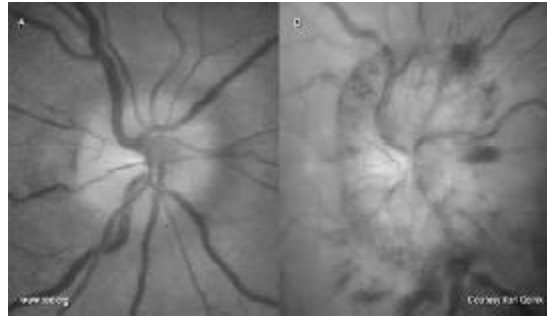


Fig. 7

Effects of Anti TB Drugs on eyes

Ethambutol toxicity: Green colour visual field is first lost. If treated by hydroxycobalamine and stopping ethambutol, it is reversible. If not treated optic neuritis and optic atrophy may occur.

Isoniazid and streptomycin can rarely cause optic neuritis.

Icterus due to hepatotoxicity can occur due to rifampicin, isoniazid and pyrazinamide.

References

1. Abrams J, Schlagel TF Jr. The role of Isoniazid therapeutic test in tuberculous uveitis. *Am J Ophthal* 1982; 94 : 511.
2. Das TP, Namperumalswamy P. Photocoagulation in Eales disease. *Acta XXVI Int Cong Ophthal* 1990.
3. Duke Elders Vol V. System of ophthalmology C.V Morg by company 1967; 10 : 222.
4. Namperumalswamy, Kelkar AP, Das TP. Vitreous Surgery in Eales disease. *Acta XXVI Int Cong Ophthal*, Singapore, 1990.
5. Murthy KR, Abrams. Eales Disease Pros. *AIOS* 1977; 33 : 323.
6. Rich AR, Mc Cordock H. Pathogenesis of Tuberculous Meningitis: John Hopkins Hospital: 1933; 52 : 5.
7. Sorsby A. Phlyctenular Ophthalmia. *Br J Ophthal* 1942; 30-159.
8. Woods AC. Pathogenesis and treatment of ocular TB. *Archives of Ophthalmology* 1954; 52-175.
9. Woods AC. Endogenous inflammation of the uveal tract: Baltimore, Williams and Wilkins:1961.