

# Primary Tuberculosis of Rectum Mimicking Malignancy

BM Subnis\*, GD Bakhshi\*\*, Aftab Shaikh\*\*\*, Ashok Borisa\*\*\*, Vinit Wakade\*\*\*\*, Yatin Kher\*\*\*\*, Ashis Patnaik\*\*\*\*, C Alagappan\*\*\*\*, Nilofar Jamadar+

## Abstract

Gastrointestinal tract is commonly affected by tuberculosis; however isolated tuberculous involvement of the rectum is rare. We report a relatively uncommon case of isolated rectal tuberculosis in a 31 year old female, who presented with rectal bleeding and painful defaecation. It clinically and radiologically mimicked malignancy but biopsy showed tuberculosis. Patient was started on AntiKoch's treatment (AKT) and patient responded well. A brief discussion of the case and review of literature is presented.

## Introduction

Tuberculosis (TB) of gastrointestinal tract (GIT) may be primary or secondary to a primary focus elsewhere. Primary intestinal tuberculosis is usually because of bovine tubercle bacilli through milk. Decreased incidence of primary tuberculosis has been seen due to pasteurization of milk.<sup>1</sup> Rectal TB can present with annular stricture or with ulceration of mucosa with fibrosis. Its radiological and endoscopic appearances may be extremely similar to malignant rectal lesion and only biopsy can clinch the diagnosis. So histopathology is the key for the diagnosis of rectal tuberculosis.<sup>2</sup> We present a case of rectal tuberculosis which simulated malignancy and responded well to antituberculous treatment.

## Case Report

A 31 year old female presented with bleeding per rectum and altered bowel habits since 3 months. Per rectal bleeding during defaecation was associated with

pain. There was no history of tenesmus. Patient was not having history of Koch's or Koch's contact in the past. Clinically she was having pallor. Per abdomen examination was unremarkable. On per rectal examination there was hard annular growth about 5 cm from anal verge which was bleeding on touch. Her biopsy was taken and clinical impression of rectal malignancy was formed. Ultrasonography of pelvis and abdomen was normal. Barium enema showed an annular lesion in rectum suggestive of growth in rectum (Fig. 1). Computed tomography showed a longitudinal growth 8 cm in length and about 5 cm from anal verge having irregular margins suggestive of malignancy with widening of presacral space (Figs. 2, 3). Per rectal biopsy was suggestive of tuberculous proctitis. Erythrocyte sedimentation rate of the patient was 81 mm at the end of 1 hr and Mantoux test was strongly positive. Patient's TB polymerase chain reaction (PCR) of the tissue was also highly suggestive of tuberculosis. The patient was started on four drug Anti-Koch's treatment (AKT) of cap. rifampicin(R) 450 mg, tab. isoniazid (H) 300 mg, tab. ethambutol (E) 800 mg, tab. pyrazinamide (Z) 1500 mg for three months and two drugs HR for six months. Patient responded well to AKT and after nine months of follow-up she is completely asymptomatic and her rectal growth has also receded in size.

## Discussion

Tuberculosis of GIT can involve any portion of bowel extending from oesophagus to anus however; involvement of bowel distal to ileocaecal junction is infrequently seen.<sup>1</sup> Anorectal tuberculosis may present in six

\*Professor of Surgery, Head of the Department and Unit Head, Department of General Surgery; \*\*Asso. Prof.; \*\*\*Lecturer; \*\*\*\*Resident, Department of Surgery and +Department of Radiology, Grant Medical College and Sir J.J. Group of Hospitals, Mumbai - 400 008.

Reprinted from : BHJ 2008; 50 (2) : 283-85

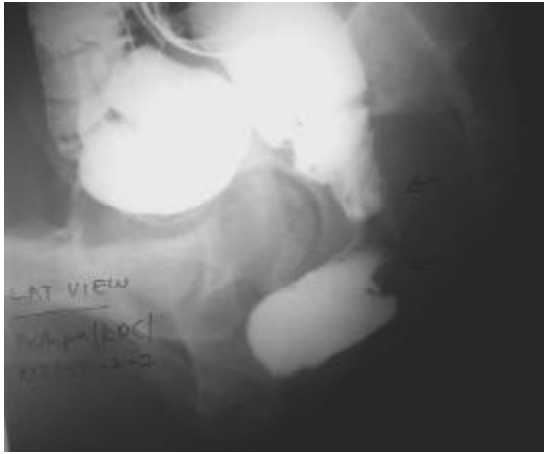


Fig. 1 : Barium enema showing growth in the rectum with narrowing.

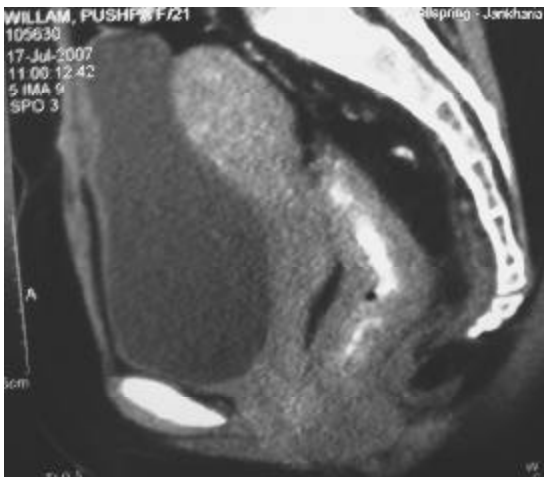


Fig. 2 : CT scan showing growth in the rectum with widened presacral space.

forms as; i) fistula in ano, which is the commonest manifestation; ii) ulcer with undermined edge which is the next frequent form; iii) stricture which is short annular and firm with nodular surface which needs to be differentiated from malignancy, iv) multiple small mucosal ulcer as a part of miliary disease, v) lupoid form presenting as a sub mucosal nodule with mucosal ulceration, vi) verrucous form with smooth warty excrescences.<sup>3</sup> Bockus et al have reported 70% of cases of primary infection with tuberculosis

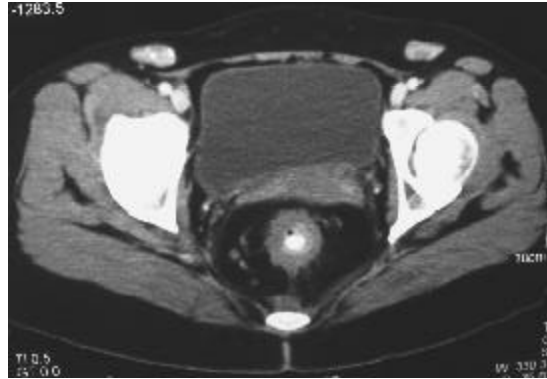

Fig. 3 : CT scan showing circumferential (annular) thickening of rectum.

to have hyperplastic or hypertrophic forms while secondary lesions to be of ulcerative types in GIT.<sup>4</sup>

Colorectal tuberculosis is common in developing countries; however, its diagnosis is difficult. Abdominal pain, fever, anorexia, weight loss, and change in bowel habit are seen in more than 50% of the patients.<sup>5</sup> Since tuberculosis causes obliterative endarteritis, massive bleeding per rectum associated with colonic TB is rare. However, massive haematochezia is associated with rectal TB resulting from mucosal trauma caused by the scybalous stool traversing the stricturous segment.<sup>6</sup> Our patient too, presented with per rectal bleeding and pain during defaecation but without tenesmus. Patient had hard annular growth about 5 cm from anal verge and was bleeding on touch.

In absence of pulmonary tuberculosis, diagnosis of rectal tuberculosis is very difficult as it mimics Crohn's disease or malignancy.<sup>7</sup> Usually after clinical suspicion all patients are subjected to barium enema or CT scan which most of the times mimics malignancy on appearance. Puri *et al* recommended tuberculosis as a possible aetiology in isolated rectal strictures and advised exclusion of malignancy on two separate biopsies.<sup>2</sup> Granulomas are demonstrated in 27% of

biopsies and cultures are positive in 36% of cases.<sup>3</sup> In view of the negative cultures and stains for mycobacterium tuberculosis, a polymerase chain reaction is recommended.<sup>2</sup> Perirectal and perianal fibrosis will cause stricture and show widened presacral space on CT scan.<sup>6</sup> Histopathology is the important investigation from the point of diagnosis in tuberculosis of rectum.<sup>8</sup>

Provisional diagnosis of carcinoma rectum was considered in our patient in view of the barium enema findings of circumferential rectal narrowing, and on computed tomogram widened presacral space and mucosal irregularity with longitudinal stricture. However, proctoscopic biopsy revealed granulomatous lesion with caseation which is characteristic of tuberculosis. Even TB PCR was highly suggestive of Koch's.

Antitubercular drugs have changed the dismal outlook for patients with secondary tuberculous enteritis. Chemotherapy also has made surgery safe and often curative. Many reports however suggest that the hypertrophic form of gastrointestinal tuberculosis do not respond to drug therapy.<sup>1,5</sup> Surgical treatment may be required if: a) Stenosis persists after 3 to 6 months of antitubercular treatment. b) It is difficult to differentiate from malignancy. c) Malignancy and tuberculosis coexist.<sup>5</sup>

Our patient responded well to AKT. Hence surgery was not required. This is an unusual

case of hyperplastic form of rectal TB responding well to AKT. Hence, we can treat a patient of rectal tuberculosis by chemotherapy rather than subjecting the patient to abdominoperineal resection by misdiagnosing the case as malignancy. However, further studies are required to support this fact.

#### References

1. Rege SA, Umman P, Nunes Q, Joshi A, Rohandia OS. Rectal tuberculosis simulating malignancy — A Case Report and Review. *Bombay Hospital Journal* 2002; 44 : 2.
2. Puri AS, Vij JC, Kumar N, *et al.* Diagnosis and outcome of isolated rectal tuberculosis. *Dis Colon Rectum* 1996; 39 (10) :1126-9.
3. Rai RR, Nijhawan S, Bhargava N, Nepalia S, Pokhrana DS. Rectal tuberculosis —a case report. *Indian J Med Res* 1993: 35-37.
4. Bockus HL. In *Gastroenterology* 2, 2nd ed. WB Saunders Co. Philadelphia. 1964; 334.
5. Singh V, Kumar P, Kamal J, Prakash V, Vaiphei K, Singh K. Clinicocolonoscopy profile of colonic tuberculosis, India. *Am J Gastroenterol* 1996; 91 (3) : 565-8.
6. Sharma MP, Bhatia V. Abdominal tuberculosis Review Article. *Indian Journal Med Res* 2004; 120 : 305-15.
7. Panton ON, Sharp R, English RA, Atkinson KG. Gastrointestinal tuberculosis - The great mimic still at large. *Dis Colon Rectum* 1985; 28 (6) : 446-50.
8. Das PC, Radhakrishna K, Rao PL. Rectal stricture: a complication of tuberculosis. *J Pediatric Surgery* 1996; 31 (7) : 983-4.